

**PATIENT PRESENTING CLINICAL SIGNS**

Cruz Unkert Pre sx echo- hm 2/6  
 ECG= fascicular block BNP normal.

**SPECIES** Abnormal PE/Chem/CBC/UA Results: WNL  
 Feline

**ULTRASONOGRAPHIC EXAMINATION OF THE HEART**

BREED	FELINE CARDIAC PARAMETERS	BODY WEIGHT	HR (BPM)	IVSd (cm)	LVIDd (cm)	LVWd (cm)	FS (%)	EF (%)
DSH								
<b>SEX</b>	<b>NORMAL PARAMETER</b>	-----	150-240	0.3-0.6	1.0-2.1	0.25-0.6	35-67	80-100
<b>MN</b>	<b>PATIENT</b>	11lb	229	0.45	1.44	0.45	49	83
<b>AGE</b>	FELINE CARDIAC PARAMETERS	LA/AO M-Mode	LA/AO HEART BASE (Sisson)	LAD LA MAX 4 Chamber		LVOT VEL. (m/s)	RVOT VEL. (m/s)	IVRT (m/)
6yr	<b>NORMAL PARAMETER</b>	<1.5	1.6	0.7-1.7		<1.6	<1.3	40-60
<b>WEIGHT</b>	<b>PATIENT</b>	--	1.34	1.3		--	1.1	NM
11lb	Sisson D et al. JVIM 1991; 5: 232, Jacobs et al. Am J Vet Res 1985; 46:1705							

**INTERPRETED BY Cardiac Presentation**

R. McKenzie Daniel, DVM, DABVP (Canine and Feline)

The echocardiogram in this patient demonstrated normal left atrial size based on 2 separate LA measurements. The cranial and caudal mitral valve leaflets presented normal linear structure and kinetics. No overt MR present on Doppler. The left ventricle presented normal thicknesses with linear contour and was not dilated nor restricted. The myocardium presented normal echogenicity without subjective evidence of significant fibrotic or ischemic disease. The contractility of the ventricular walls was adequate and in normal range for this patient evidenced by the fractional shortening measurement and subjective evaluation of the different regions and angles of the myocardium. The left ventricular outflow tract demonstrated normal laminar flow and subjective structural integrity. The right atrium and auricle revealed normal size, structure and content. No evidence of masses was noted or chamber overload. Tricuspid valvular assessment demonstrated adequate linear morphology and kinetics. No overt TR present on Doppler. The right ventricle was of normal size (1/3 diameter of LV), chordae structure, myocardial echogenicity and thickness. Pulmonic tract assessment revealed normal valve structure, laminar flow, and diameter (approx.1:1 pa/ao ratio). Normal measured RVOT velocity was present. No visible pericardial or free pleura fluid was noted or extra cardiac pathology in the visible planes. The cranial mediastinum and pericardial regions were free of masses in the visible window.

**IMAGING PERFORMED BY**

Kerri Becker

**HOSPITAL NAME**

Legacy AH

**REFERRING VET**

Dr Potenzzone

**INVOICE**  
24087

**DATE**  
03/02/2026



**PATIENT**                      **ULTRASONOGRAPHIC FINDINGS**

Cruz Unkert                      **Primary**

- Normal cardiac structure/function

**SPECIES**

Feline

**BREED**

DSH

**SEX**

MN

**AGE**

6yr

**INTERPRETATION OF THE FINDINGS & FURTHER RECOMMENDATIONS**

A definitive cause of the patient's murmur was not evident without evidence of structural or functional cardiomyopathy. No evidence of clinical issues such as left or right heart chamber enlargement, LV systolic dysfunction, clinical pulmonary hypertension or overt valvular insufficiencies was present. If no volume changes such as dehydration or anemia are present, a benign physiological flow murmur or small flow abnormality is suspected. Regardless, the lack of left or right heart chamber enlargement indicate that the hemodynamic effects of the murmur are minimal. No indication for cardiac medications. Continued conservative monitoring of the murmur is recommended. Recheck echocardiogram recommended in 6-12 months, sooner if murmur intensity increases or clinical signs suggestive of heart disease arise.

No anesthetic contraindications. Suggested anesthetic protocol may include opioid or Benzodiazepine pre-med, induction with Propofol or Alfaxalone, and appropriate gas anesthesia with avoidance of alpha 2 agonists.

**WEIGHT**

11lb

**INTERPRETED BY**

R. McKenzie Daniel,  
 DVM, DABVP  
 (Canine and Feline)

**IMAGING PERFORMED BY**

Kerri Becker

**HOSPITAL NAME**

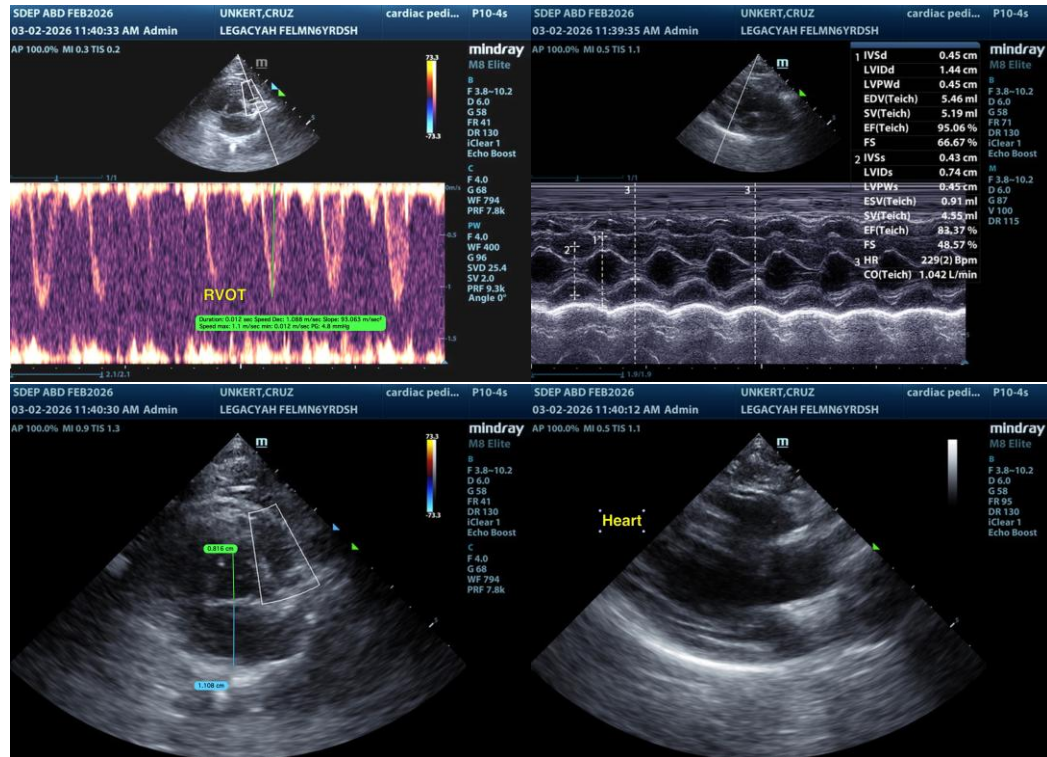
Legacy AH

**REFERRING VET**

Dr Potenzzone

**INVOICE**  
 24087

**DATE**  
 03/02/2026



The information and recommendations provided are based on the images presented by the referring



**PATIENT**

Cruz Unkert

veterinarian/sonographer. No evaluation can be communicated regarding pathology that was not visible in the image/video clips provided.

Thank you for this referral. If the clinical or image interpretation does not parallel your findings or if I can be of any further assistance, please contact me.

**SPECIES**

Feline

R. McKenzie Daniel, DVM, DABVP (Canine/Feline Practice)  
[info@sonopath.com](mailto:info@sonopath.com)

**BREED**

DSH

**SEX**

MN

**AGE**

6yr

**WEIGHT**

11lb

**INTERPRETED BY**

R. McKenzie Daniel,  
DVM, DABVP  
(Canine and Feline)

**IMAGING  
PERFORMED BY**

Kerri Becker

**HOSPITAL NAME**

Legacy AH

**REFERRING VET**

Dr Potenzzone

**INVOICE  
24087**

**DATE**  
03/02/2026